

Available online at www.sciencedirect.com

ScienceDirect

journal homepage: www.elsevier.com/locate/radcr

Case report

Blue rubber bleb nevus syndrome: Presentation of a case and review of the literature [☆]

Fabricio Andres Lasso Andrade, MD. MSP.^{a,*}, Jorge Alejandro Cadena Arteaga, MD. MSP.^b, Viviana Lizeth Echeverry Morillo, MD^c, Ángela María Fajardo Arteaga, MD^d, Jenny Alexandra Jurado Pantoja, MD^e, Migdalia Zamirna Zuley Lasso Anaconda, MD^f, Paula Andrea Nieto Lozano, MD^g, Daniela Steffany Possos Obando, MD^d, María Alejandra Palacios Rodríguez, MD^h, Madelen Alexandra Ortiz Cárdenas, MD^g, Hermes Albeiro Ortega Díaz, MD^g, Diana Yulieth Ramírez Anaconda, MD^f, Rodrigo Zanabria Zarmienta, MDⁱ

^aMD. Universidad del Cauca, Especialista Epidemiología. Universidad Autónoma de Bucaramanga, Residente Anestesiología y Reanimación, Universidad Nacional de Colombia Bogotá D.C., Correo electrónico: fabriciolasso@gmail.com. Bogotá D.C, Colombia.

^bEspecialista en Radiología, Universidad del Valle, Cali, Colombia

^cUniversidad Santiago de Cali, Mocoa-Putumayo.

^dUniversidad de Caldas, Putumayo.

^eUniversidad del Tolima, Mocoa-Putumayo.

^fFundación Universitaria San Martín, Mocoa-Putumayo.

^gUniversidad Cooperativa de Colombia, Mocoa-Putumayo.

^hUniversidad de Manizales, Puerto Asís - Putumayo.

ⁱUniversidad Industrial de Santander, Bogotá D.C.

ARTICLE INFO

Article history:

Received 13 April 2021

Revised 29 April 2021

Accepted 30 April 2021

Available online 8 June 2021

Keywords:

Anemia

Blue rubber bleb nevus syndrome

Hemangioma

Vascular malformations

Gastrointestinal bleeding

ABSTRACT

Blue Rubber Bleb Nevus Syndrome, is a rare condition characterized by skin lesions caused by vascular malformations most frequently associated with lesions of the gastrointestinal tract, although rare, it can present with lesions in the central nervous system, thyroid, liver, spleen and lungs; common symptoms are: digestive tract bleeding and iron deficiency anemia. The main manifestation are skin lesions that are characterized by being button-like, with a bluish tint, covered by skin, called blue nevus with a rubbery consistency due to its rubber-like consistency. We present a case of Blue Rubber Bleb Nevus Syndrome with involvement in the central nervous and gastrointestinal systems.

© 2021 The Authors. Published by Elsevier Inc. on behalf of University of Washington.

This is an open access article under the CC BY-NC-ND license

(<http://creativecommons.org/licenses/by-nc-nd/4.0/>)

[☆] Competing Interests: The authors have declared that no competing interests exist.

* Corresponding author.

E-mail address: fabriciolasso@gmail.com (F.A. Lasso Andrade).

<https://doi.org/10.1016/j.radcr.2021.04.086>

1930-0433/© 2021 The Authors. Published by Elsevier Inc. on behalf of University of Washington. This is an open access article under the CC BY-NC-ND license (<http://creativecommons.org/licenses/by-nc-nd/4.0/>)

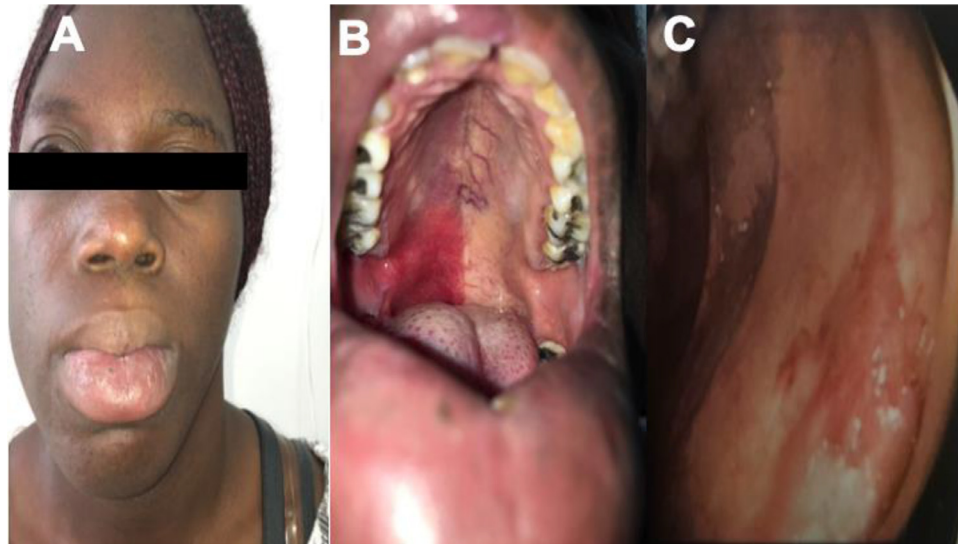


Fig. 1 – (A) Blue nevus on the lower lip. (B) Pink macula on hard palate. (C) Cecal region angiodysplasia under colonoscopy.

Introduction

Blue Rubber Bleb Nevus Syndrome (BRBNS) is a rare condition characterized by skin lesions caused by vascular malformations associated more frequently with lesions of the gastrointestinal tract [1], however, there are reports of association with lesions in the system central nervous system, thyroid, liver, spleen and lungs, common symptoms are: digestive tract bleeding and iron deficiency anemia, serious complications such as torsion and intussusception [2], cerebral infarction or hemorrhage [3], compression of the cord can also occur spinal cord [4], chronic cough and even death [5]. We present a case of BRBNS with involvement in the central nervous and gastrointestinal systems.

Case report

A 17-year-old female patient, without significant family history, with a clinical picture of 15 years of evolution consisting of untreated seizure syndrome associated with a blue nevus in her lower lip. She was admitted to the emergency department due to the presentation of asthenia, adynamics, and moderate headache, with no evidence of external bleeding. On physical examination, she was hemodynamically stable, afebrile, pale conjunctivae, presence of blue nevus on the lip and macula on the hard palate (Fig. 1). Anemia study is performed with evidence of microscopic bleeding (positive occult blood in feces) and microcytic and hypochromic anemia. The gastroenterology service determines the performance of a colonoscopy under sedation in which angiodysplasia is observed at the Cecal level (Fig. 1). Due to his seizure history, a study was carried out using contrast-enhanced magnetic resonance imaging (MRI) of the brain, which shows findings compatible with choroidal telangiectasia and atrophy of the right cerebral hemisphere (Figs. 2

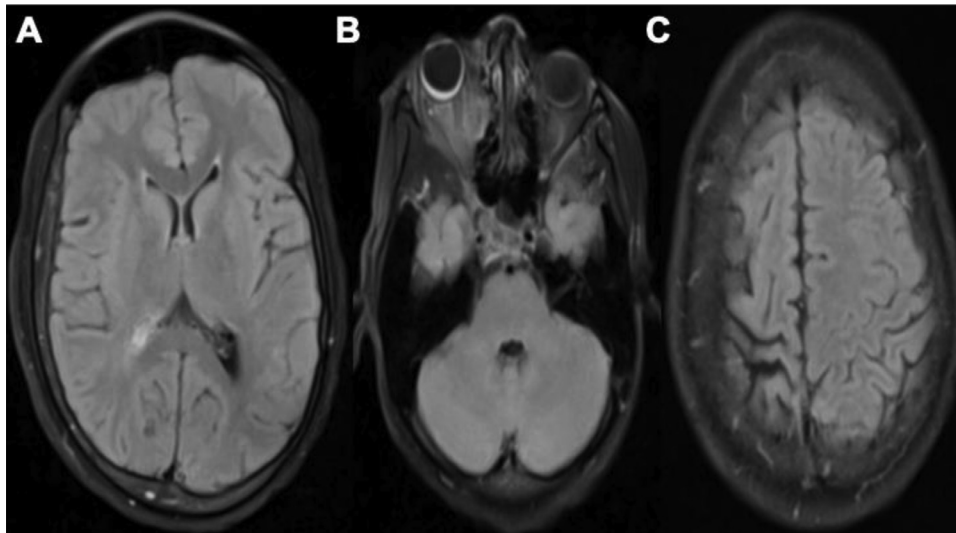
and 3). Normal abdomen ultrasound. A biopsy of lesions in her lower lip is performed, showing a benign vascular lesion that affects from the superficial to the deep dermis, with dilated and cavernous vessels, interconnected vascular channels with phenomena of thrombosis and vascular recanalization. The diagnosis of BRBNS was made, beginning an interdisciplinary management with supplementation of iron, folic acid and valproic acid, with a 12-month follow-up where the patient has not presented new seizures or need for transfusions.

Discussion

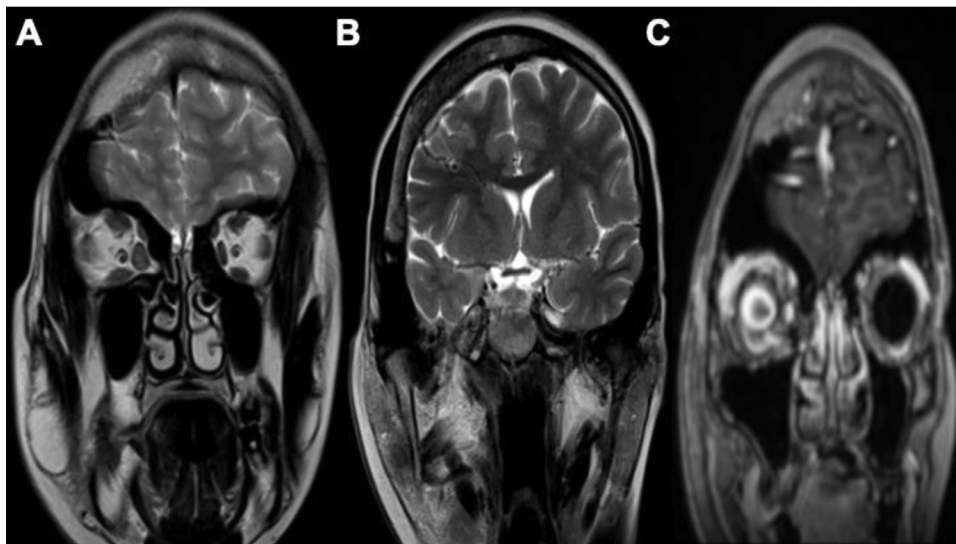
BRBNS, was first described by Gascoyen in 1860, however, William B. Bean was the one who coined the term "blue rubber bleb nevus syndrome" in 1958. Recently Rudolf Happle proposed the name "blue rubber bleb angiomatosis" in 2010, referring to the type of malformations it presents [6].

BRBNS is known to have no sex predilection and can manifest at any age. Generally, skin lesions appear shortly after birth, their size varies and increases in number and size directly proportional to age and with a history of soft tissue trauma in the anatomical sites where they occur. These lesions generally do not bleed spontaneously or undergo malignant changes [7].

The clinical manifestations vary according to the degree of organ involvement, in one of the largest reviews, where 120 cases were analyzed, the main manifestation was cutaneous with 93% of the patients, the lesions are characterized by being similar to buttons, with a bluish tint, covered by skin, called blue nevus with a rubbery consistency, they vary in number, size and depth from 1 mm to 10 cm in diameter, with extension to muscles and joints, they are located preferably on the trunk, extremities and plants, some cause pain and sweating. The pain can be caused by the contraction of the smooth muscle fibers that surround the angioma and sweating, possibly due to the proximity of the nevi to the sweat glands [8].



A. MRI with contrast, in Axial section, Flair sequence, hyperintensity of the choroid plexus is observed on the right side corresponding to its hypertrophy. **B.** Choroidal hyperintensity in the right orbit corresponding to choroid telangiectasia. **C.** Atrophy of the right cerebral hemisphere and hyperostosis of the right hemisphere.



A. MRI with contrast, in Axial section, Flair sequence, hyperintensity of the choroid plexus is observed on the right side corresponding to its hypertrophy. **B.** Choroidal

Fig. 2 – (A) MRI with contrast, in Axial section, Flair sequence, hyperintensity of the choroid plexus is observed on the right side corresponding to its hypertrophy. (B) Choroidal hyperintensity in the right orbit corresponding to choroid telangiectasia. (C) Atrophy of the right cerebral hemisphere and hyperostosis of the right hemisphere.

Gastrointestinal involvement occurs in 76% of cases, in whom hemangiomas can affect any anatomical site from the mouth to the anus, preferably in the small intestine, when they affect the colon they are more frequent in the rectum or distal areas, these lesions can cause different clinical manifestations such as: hematemesis, melena or rectal bleeding, although sometimes the only manifestation is hidden bleeding that causes iron deficiency anemia, as in the case of our patient [5]. Lesions can present in various forms, including poly-

lobulated, nodular, sessile, pedunculated, or ulcerated. The main complications are: volvulus, intussusception, intestinal infarction, in the worst case, hypovolemic shock caused by gastrointestinal bleeding [9].

Central nervous system involvement has been reported in 13% of cases where hemangiomas and telangiectasias can cause cerebral infarction or hemorrhage [3]. Skeletal muscle is affected in 9% of cases, finding hemangiomas in the vertebral bodies that cause spinal compression [4].

The diagnosis is clinical, it is established through findings on physical examination, diagnostic images and endoscopy, to determine the extent of the lesions and involvement of underlying organs [10].

There are three types of well-described skin lesions in this syndrome. Our patient presents a lesion on her lower lip compatible with lesions type II [9]: type I, large, disfiguring venous malformations that progressively increase in size and can obstruct vital tissues. Type II, the most common manifestation, is the typical description with a consistent rubbery, thin-walled sac filled with bluish-colored blood, easily compressible and slowly refilling when pressure is released; asymptomatic or painful with hyperhidrosis. Type III: blue-blackish irregular macula or papule, together with a pigmented nevus and rarely pales under pressure.

The ultrasound study is the initial image of choice since it is the least invasive, this can be performed endoscopically if we suspect gastrointestinal venous malformations, it must be performed by a specialist in radiology with experience in vascular anomalies, if the ultrasound is not conclusive or not it is possible to perform, then it is indicated to perform MRI with contrast in the compromised anatomical place, other studies include CT, studies with Barium where it is possible to detect filling defects or sessile “polyps” with a wide base. Angiography is a useful alternative to visualize the lesions, mainly to detect sites of active bleeding [10].

For nevi with blue rubber blisters found on the skin can be examined under dermoscopy, the most frequent findings under this technique are: superficial light red arborizing veins, macules with indefinite borders on the palms and soles or mucous membranes, and blue nodules -violet with gaps divided by white linear structures [11].

Treatment is aimed at treating the symptoms, patients can benefit from the administration of iron when there are clinical manifestations of anemia, for gastrointestinal malformations several options are described, among them the most used is endoscopic sclerotherapy, band ligation or laser photocoagulation. Resection of portions of the gastrointestinal tract may be necessary when there is significant involvement in order to prevent life-threatening bleeding, hence the importance of periodic endoscopic monitoring of the evolution of the lesions [12].

In pharmacological management, different treatments with variable response have been described, among these the somatostatin analogues, such as subcutaneous octreotide used in order to reduce splanchnic blood flow in patients with gastrointestinal bleeding, other pharmacological agents reported as effective they include corticosteroids, interferon-alpha, IVIG, and vincristine [13].

BRBNS must be differentiated from hereditary hemorrhagic telangiectasia (Osler-Weber-Rendu syndrome), Klippel-Trenaunay syndrome, and Maffucci syndrome. All of these diseases are characterized by different forms of vascular malformations. Osler-Weber-Rendu syndrome is characterized by hemorrhagic pinpoint angiomas, recurrent epistaxis, telang-

iectasia and always have a positive family history. Maffucci syndrome presents diffuse vascular malformations in the skin and soft tissues, bone malformations, and chondrodysplasia. Klippel-Trenaunay-Weber syndrome is characterized by varicosities, hypertrophy, and deformities of soft tissues and bones [13].

Patient consent

We declare that the patient described in this study gave informed consent prior to inclusion in this study.

REFERENCES

- [1] Teixeira MG, Perini MV, Marques CF, Habr-Gama A, Kiss D, Gama-Rodrigues JJ. Blue rubber bleb nevus syndrome: case report. *Revista do Hospital das Clinicas* 2003;58(2):109–12.
- [2] Jin XL, Wang ZH, Xiao XB, Huang LS, Zhao XY. Blue rubber bleb nevus syndrome: a case report and literature review. *World J Gastroenterol* 2014;20(45):17254–9.
- [3] Krishnappa A, Padmini J. Blue rubber bleb nevus syndrome. *Indian J Pathol Microbiol* 2010;53(1):168–70.
- [4] Kamat AS, Aliashkevich AF. Spinal cord compression in a patient with blue rubber bleb nevus syndrome. *J Clin Neurosci* 2013;20(3):467–9.
- [5] Gilbey LK, Girod CE. Blue rubber bleb nevus syndrome: endobronchial involvement presenting as chronic cough. *Chest* 2003;124(2):760–3. doi:10.1378/chest.124.2.760.
- [6] Lee C, Debnath D, Whitburn T, Farrugia M, Gonzalez F. Synchronous multiple small bowel intussusceptions in an adult with blue rubber bleb naevus syndrome: Report of a case and review of literature. *World J Emerg Surg* 2008;3:3. doi:10.1186/1749-7922-3-3.
- [7] Kaur T, Singh S. Blue rubber bleb nevus syndrome: A case report. *Indian J Dermatol* 2014;59(1):98–9.
- [8] Kassarian A, Fishman SJ, Fox VL, Burrows PE. Imaging characteristics of blue rubber bleb nevus syndrome. *AJR Am J Roentgenol* 2003;181(4):1041–8.
- [9] Jin XL, Wang ZH, Xiao XB, Huang LS, Zhao XY. Blue rubber bleb nevus syndrome: a case report and literature review. *World J Gastroenterol* 2014;20(45):17254–9.
- [10] Agnese M, Cipolletta L, Bianco MA, Quitadamo P, Miele E, Staiano A. Blue rubber bleb nevus syndrome. *Acta Paediatr* 2010;99(4):632–5.
- [11] Arena M, Virdis M, Morandi E, Viaggi P, Pisani A, Opocher E, et al. Blue rubber bleb nevus syndrome: combined surgical and endoscopic treatment. *Endoscopy* 2015;47:E372–3 Suppl 1 UCTN.
- [12] Aihara M, Konuma Y, Okawa K, Komai R, Kudo I, Morioka R, et al. Blue rubber bleb nevus syndrome with disseminated intravascular coagulation and thrombocytopenia: successful treatment with high-dose intravenous gammaglobulin. *Tohoku J Exp Med* 1991;163(2):111–17.
- [13] Akyuz C, Susam-Sen H, Aydin B. Blue rubber bleb nevus syndrome: promising response to sirolimus. *Indian Pediatr* 2017;54(1):53–4.